

CORRESPONDENCE

Pathology of Vaping-Associated Lung Injury

TO THE EDITOR: Despite the accumulating data on the clinical and imaging features of vaping-associated lung injury,^{1,2} its pathology is poorly understood. We reviewed lung biopsies from 17 patients (13 men; median age, 35 years [range, 19–67]), all of whom had a history of vaping (71% with marijuana or cannabis oils) and were clinically suspected to have vaping-associated lung injury. Presentation was acute or subacute in all cases, with bilateral pulmonary opacities; all but two patients presented in 2019. Eleven met the

criteria for a “confirmed” diagnosis of vaping-related lung injury; the remaining six met the criteria for a “probable” designation. In all cases, histopathological findings showed patterns of acute lung injury, including acute fibrinous pneumonitis, diffuse alveolar damage, or organizing pneumonia, usually bronchiolocentric and accompanied by bronchiolitis (Fig. 1; also see the Supplementary Appendix, available with the full text of this letter at NEJM.org). No histologic findings were specific, but foamy macrophages and pneu-

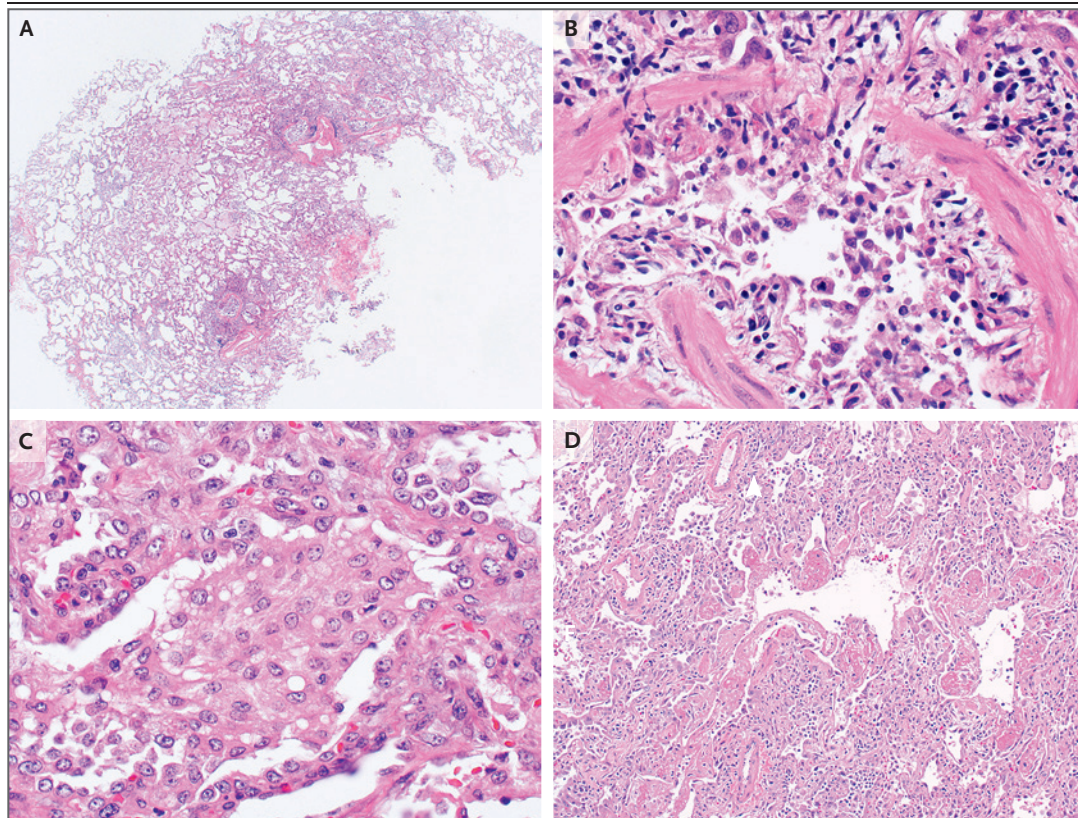


Figure 1. Histopathology of Acute Lung Injury Associated with Vaping.

Most cases showed airway-centered acute lung injury (Panel A), often with severe bronchiolitis accompanied by marked mucosal edema, sloughing of bronchiolar epithelium, and peribronchiolar organization (Panel B). All cases showed accumulation of foamy or vacuolated macrophages in peribronchiolar airspaces with pneumocyte vacuolization (Panel C). Four cases showed severe injury, with diffuse alveolar damage and hyaline membranes (Panel D); two of these patients died.

mocyte vacuolization were seen in all cases and may be useful diagnostic clues in an appropriate clinical context. Pigmented macrophages were sometimes present but were never a dominant feature. Neutrophils were often prominent, but eosinophils were rare and granulomas were not seen. In two cases, bronchioloalveolar lavage fluid was available and contained abundant foamy macrophages. Despite treatment with glucocorticoids and maximum supportive care, two patients with diffuse alveolar damage died.

To date, few reports of vaping-associated lung injury have included histopathological findings. Our cases corroborate many of these descriptions and provide some preliminary insight into the pathogenesis of this injury. Much recent attention has been given to the possibility that vaping-associated lung injury may represent exogenous lipid pneumonia.³ However, none of our cases showed histologic evidence of exogenous lipid pneumonia and no radiologic evidence thereof has been found²; this calls into question the diagnostic utility of identifying lipid-laden macrophages or performing oil red O staining on bronchioloalveolar lavage fluid as a marker of vaping-associated lung injury, as has been proposed.^{3,4} The significance of this observation remains unclear, particularly in patients with a known vaping history; until more data accumulate, our observations suggest that this finding should be interpreted with caution, as it may simply be a marker of exposure and not necessarily a marker of toxicity. Although it is difficult to discount the potential role of lipid, we believe that the histologic changes instead suggest that vaping-associated lung injury represents a form of airway-centered chemical pneumonitis from one or more inhaled toxic substances rather than exogenous lipid pneumonia as such, but the agents responsible remain unknown.

Yasmeen M. Butt, M.D.
Maxwell L. Smith, M.D.
Henry D. Tazelaar, M.D.
Laszlo T. Vaszar, M.D.
Karen L. Swanson, D.O.

Mayo Clinic
Scottsdale, AZ

Matthew J. Cecchini, M.D., Ph.D.
Jennifer M. Boland, M.D.
Melanie C. Bois, M.D.
James H. Boyum, M.D.
Adam T. Froemming, M.D.

Mayo Clinic
Rochester, MN

Andras Khor, M.D., Ph.D.
Isabel Mira-Avendano, M.D.

Mayo Clinic
Jacksonville, FL

Aiyub Patel, M.D.

UnityPoint Health
Peoria, IL

Brandon T. Larsen, M.D., Ph.D.

Mayo Clinic
Scottsdale, AZ
larsen.brandon@mayo.edu

Disclosure forms provided by the authors are available with the full text of this letter at NEJM.org.

This letter was published on October 2, 2019, at NEJM.org.

1. Layden JE, Ghinai I, Pray I, et al. Pulmonary illness related to e-cigarette use in Illinois and Wisconsin — preliminary report. *N Engl J Med*. DOI: 10.1056/NEJMoa1911614.
2. Henry TS, Kanne JP, Kligerman SJ. Imaging of vaping-associated lung disease. *N Engl J Med*. DOI: 10.1056/NEJMc1911995.
3. Maddock SD, Cirulis MM, Callahan SJ, et al. Pulmonary lipid-laden macrophages and vaping. *N Engl J Med*. DOI: 10.1056/NEJMc1912038.
4. Davidson K, Brancato A, Heetderks P, et al. Outbreak of electronic-cigarette-associated acute lipid pneumonia — North Carolina, July–August 2019. *MMWR Morb Mortal Wkly Rep* 2019;68:784-6.

DOI: 10.1056/NEJMc1913069

Correspondence Copyright © 2019 Massachusetts Medical Society.